

PATIENT

Mr Bigglesworth
Spiotti

SPECIES

Canine

BREED

Pit bull terrier

SEX

MN

AGE

13 years

WEIGHT

33 kg

INTERPRETED BY

Remo Lobetti, BVSc,
MMedVet (Med), PhD,
Dipl. ECVIM

**IMAGING PERFORMED
BY**

Brent Crutchfield, DVM

HOSPITAL NAME

Treasure Coast Animal
Emergency

REFERRING VET

Dr Cail

INVOICE

303179

DATE

8/9/22

PRESENTING CLINICAL SIGNS

History: Follow up ultrasound. Vomited small amount of plastic.

Physical Examination: N/A.

Urinalysis: N/A

CBC: N/A.

Serum Biochemistry: N/A.

Radiographic Findings: N/A.

ULTRASONOGRAPHIC EXAMINATION OF THE ABDOMEN

Urinary System

Full urinary bladder with a normal thickness (0.3 cm) and appearance of the wall. Normal anechoic urine with no sediment or uroliths evident.

Normal proximal urethra and iliac blood vessels.

Normal iliac lymph nodes (1 cm). Ureters not visualized.

Normal renal size (left 6.4 cm, right 6 cm), echogenic appearance, cortico-medullary differentiation, pelvis, and capsule. Bilateral pinpoint mineralization. Focal small non-obstructive renolith (0.5 cm) in the left kidney.

Reproductive System

Small hypoechogenic prostate (1.4 cm).

Adrenal Glands

Normal shape, echogenic appearance, position but bilaterally enlarged. Left 0.95 cm, left 1.2 cm.

Spleen

Normal size and echogenic appearance. Focal mottled echogenic parenchymal nodule (1.5 cm) in the body of the spleen. Smooth homogenous parenchyma, smooth curvi-linear capsule, and normal vasculature. No evidence of inflammatory, neoplastic, infarction, or infiltrative changes noted.

Liver

Normal size, echogenic appearance, and portal markings. Focal hyperechogenic parenchymal nodule (0.9 cm) in the right lobe. No masses evident. Full gall bladder containing normal anechoic bile. Thickened (0.8 cm) and hyperechogenic appearance of the gall bladder wall with surrounding edema. Normal bile duct.



PATIENT

Mr Bigglesworth
Spiotti

SPECIES

Canine

BREED

Pit bull terrier

SEX

MN

AGE

13 years

WEIGHT

33 kg

INTERPRETED BY

Remo Lobetti, BVSc,
MMedVet (Med), PhD,
Dipl. ECVIM

IMAGING PERFORMED BY

Brent Crutchfield, DVM

HOSPITAL NAME

Treasure Coast Animal
Emergency

REFERRING VET

Dr Cail

INVOICE

303179

DATE

8/9/22

Gastrointestinal

Normal appearance of the stomach, duodenum, small intestine, ileo-cecal junction, and colon with no loss of layering, normal wall thickness (duodenum 0.47 cm, colon 0.15 cm) and peristaltic activity, and no distension of the lumen.

Pancreas

Enlarged and irregular with a mottled echogenic appearance. Hyperechogenic appearance of the mesentery and fat surrounding the pancreas.

Free Abdomen

No mesenteric lymphadenomegaly.

Visible pancreatic lymph node (1.2 cm) with a normal shape and echogenic appearance. No ascites.

ULTRASONOGRAPHIC FINDINGS

Primary findings:

- Pancreatitis.
- Bilateral adrenomegaly.
- Cholecystitis.
- Hepatic and splenic nodules.

Secondary findings:

- Renolith.

INTERPRETATION OF THE FINDINGS & FURTHER RECOMMENDATIONS

This ultrasound is similar to that of 7/6 although the mass effect of the pancreas that was present has resolved.

The appearance of the pancreas is consistent with chronic-active pancreatitis.

Etiologies for the adrenomegaly would be age-related, disease stress, and emerging pituitary-dependent Cushing's disease.

The cholecystitis is most likely secondary to the pancreatitis.

Etiologies for the splenic and hepatic nodules would be reactive hyperplasia, granuloma, organized abscessation, and neoplasia.

Further assessment would be FNA cytology of the spleen and liver, and adrenal function testing (ACTH stimulation/LDDS test).

Specific therapy would be dependent on an etiological diagnosis. Symptomatic therapy would be low-fat intestinal diet and NSAID analgesics as needed.



PATIENT

Mr Bigglesworth
Spiotti

SPECIES

Canine

BREED

Pit bull terrier

SEX

MN

AGE

13 years

WEIGHT

33 kg

INTERPRETED BY

Remo Lobetti, BVSc,
MMedVet (Med), PhD,
Dipl. ECVIM

IMAGING PERFORMED BY

Brent Crutchfield, DVM

HOSPITAL NAME

Treasure Coast Animal
Emergency

REFERRING VET

Dr Cail

INVOICE

303179

DATE

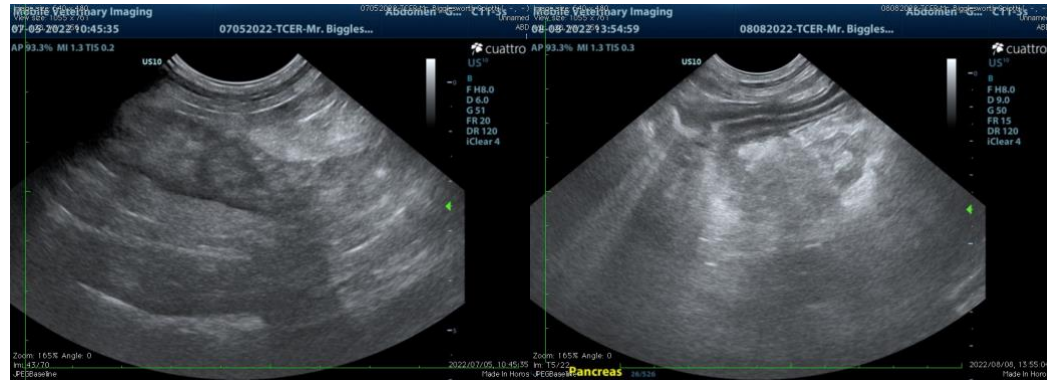
8/9/22

IMAGES

Pancreas

7/6

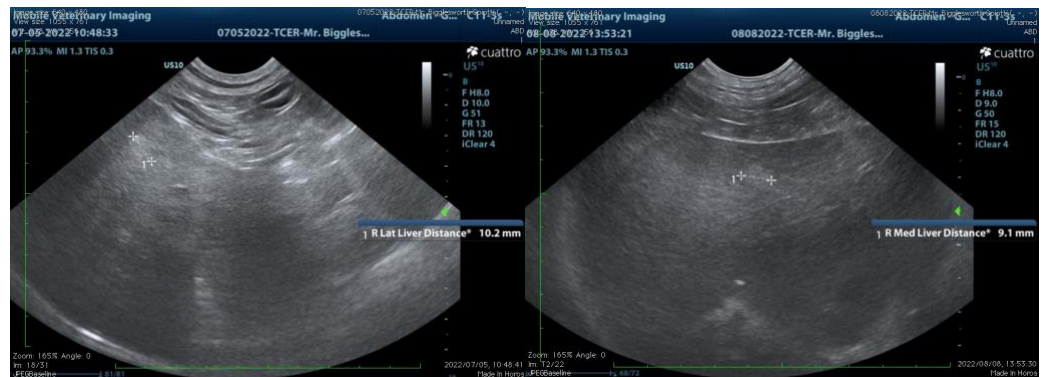
8/8



Liver

7/6

8/8





PATIENT

Mr Bigglesworth
 Spiotti

SPECIES

Canine

BREED

Pit bull terrier

SEX

MN

AGE

13 years

WEIGHT

33 kg

INTERPRETED BY

Remo Lobetti, BVSc,
 MMedVet (Med), PhD,
 Dipl. ECVIM

IMAGING PERFORMED BY

Brent Crutchfield, DVM

HOSPITAL NAME

Treasure Coast Animal
 Emergency

REFERRING VET

Dr Cail

INVOICE

303179

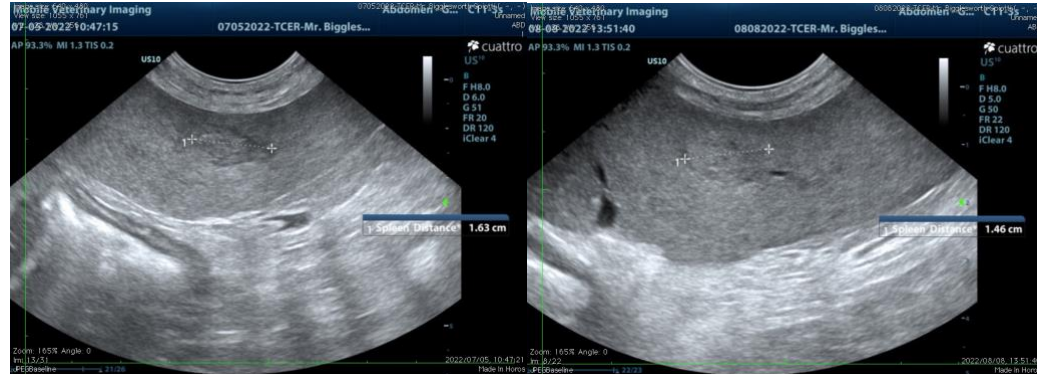
DATE

8/9/22

Spleen

7/6

8/8



The information and recommendations provided are based on the images presented by the referring veterinarian. No evaluation can be communicated regarding pathology that was not visible in the image/video clips provided.

Thank you for this referral. If the clinical or image interpretation does not parallel your findings or if I can be of any further assistance please contact me.

Remo Lobetti, BVSc, MMedVet (Med), PhD, Dipl. ECVIM (Internal Medicine)
 rlobetti@mweb.co.za